



PATIENT

Momcat Gagas

SPECIES

Feline

BREED

DSH

SEX

Female Spayed

AGE

11 years

WEIGHT

9lbs

INTERPRETED BY

Maggie Machen Lamy,
DVM, DACVIM
(Cardiology)

IMAGING PERFORMED BY

Kim Liedberg

HOSPITAL NAME

SVS Imaging WI

REFERRING VET

Dr. Panther

INVOICE

24651

DATE

6/8/22

PRESENTING CLINICAL SIGNS

History: History of intermittent lameness of left hind limb and biliary cystadenoma removal with incomplete margins 2 years ago. Grade 3/6 parasternal heart murmur noted on recent exam. Sedated with Butorphanol.

ECHOCARDIOGRAM FINDINGS

2D, m-mode, color flow and doppler imaging is available. The left ventricular wall is borderline normal in dimension. There is a diffusely hyperechoic endocardium consistent with fibrosis and remodeling. The endocardium also appears remodeled. The MV appears normal. An obstruction is not captured on Spectral or color flow; however, 2D imaging is suspicious. No MR. The left atrium is normal in size. The right atrium is normal in size. The right ventricle appears normal. Blood flow through the RVOT is mildly elevated in velocity with a dynamic profile. No obvious TR. There is no pleural or pericardial effusion seen. There are no obvious cardiac tumors.

CARDIAC CHART

FELINE CARDIAC PARAMETERS	BODY WEIGHT (kg)	HR (BPM)	IVSd (cm) (Moise, Pipers)	LVIDd (cm) (Moise, Pipers)	LVWd (cm) (Moise, Pipers)	FS (%)	EF (%)
NORMAL PARAMETER	-----	150-240	0.35-0.55	<2 (mean 1.5)	3.5-0.55	35-67	80-100
PATIENT	4.1	220	0.52	1.1	0.52	55	88
FELINE CARDIAC PARAMETERS	LA/AO (Boon)	LA/AO HEART BASE (Swe) (Abbott)	LA 2D short axis Base view (cm) (Abbott)		LVOT VEL (m/s)	RVOT VEL (m/s)	E max (m/s)
NORMAL	<1.5	<1.3	<1.2		<1.6	<1.3	<0.9
PATIENT	1.2	1.2	1.1		0.93	1.9	NM

**Note: All measurements based upon multi-modal images and methods. An average value is reported.
Adapted from June Boon, Veterinary Echocardiography, 1998
Abbott J & MacLean H JVIM 2006;20: 111-119, Moise et al. Am J Vet Res 47:1476, 1986. Pipers et al. Am J Vet Res 40:882, 1979.*

INTERPRETATION OF THE FINDINGS & FURTHER RECOMMENDATIONS

Overtly normal cardiac geriatric structure and function. The murmur is likely due to an intermittent LVOT obstruction, secondary to abnormal valve movement at elevated heart rates. This is presumptive as Doppler flows were not confirmed. There are also borderline LV wall dimensions, in addition to mild remodeling and fibrosis of the left ventricular wall. These changes may be indicative of early cardiac disease (HOCM) or may simply represent a normal variant. Serial echocardiography will be necessary to determine progression and clinical relevance of both findings. Finally, a dynamic RVOT obstruction is noted, which is a benign flow abnormality which may contribute to murmur intensity.

In patients with persistent LVOT obstruction and an elevated pressure gradient, a beta blocker is often prescribed to lower heart rate and decrease the gradient. In this patient with a mild obstruction and borderline normal LA/LV dimensions, no medications are clearly indicated.

From a structural standpoint, anesthetic risk is currently low. Avoid heart rate stimulating drugs (atropine, glycopyrrolate) unless clinically necessary. Avoid vasodilators such as acepromazine as

IMAGING PERFORMED BY

svsmobileimaging.com 309 - 737 - 3070



Clinical Sonography & Telecytology

EDUCATIONAL TELECONSULTATION SERVICES™

1-800-838-4268 info@sonopath.com SonoPath.com

PATIENT

Momcat Gagas

this can worsen obstruction. Judicious IV fluid rates are recommended to avoid fluid overload in this patient with diastolic dysfunction.

A recheck echocardiogram is recommended in 6-12 months, sooner if any clinical signs arise.

SPECIES

Feline

BREED

DSH

SEX

Female Spayed

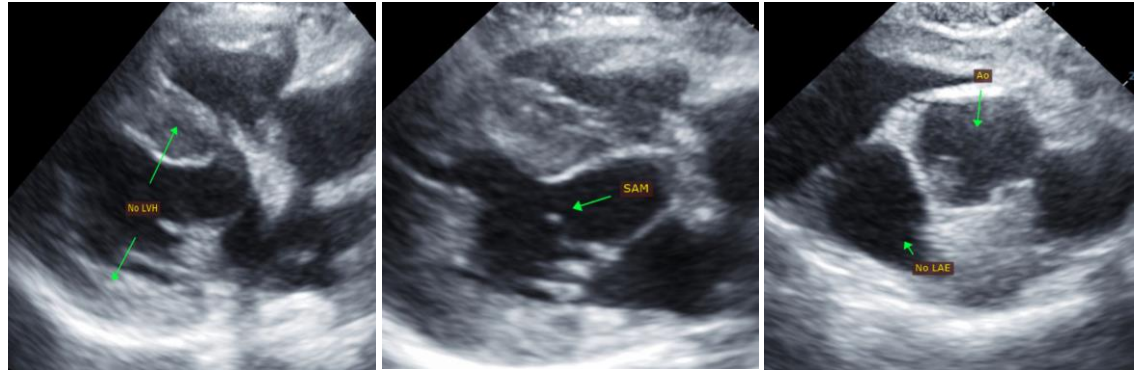
AGE

11 years

WEIGHT

9lbs

IMAGES



The information and recommendations provided are based on the images presented by the referring veterinarian. No evaluation can be communicated regarding pathology that was not visible in the image/video clips provided.

Thank you for this referral. If the clinical or image interpretation does not parallel your findings or if I can be of any further assistance, please contact me.

Maggie Machen Lamy, DVM
Diplomate of the American College of Veterinary Internal Medicine (Cardiology)
info@sonopath.com

INTERPRETED BY

Maggie Machen Lamy,
DVM, DACVIM
(Cardiology)

IMAGING PERFORMED BY

Kim Liedberg

HOSPITAL NAME

SVS Imaging WI

REFERRING VET

Dr. Panther

INVOICE

24651

DATE

6/8/22